

# Intradiscal platelet-rich plasma (PRP) injections for discogenic low back pain: an update

Michael Monfett<sup>1</sup> · Julian Harrison<sup>1</sup> · Kwadwo Boachie-Adjei<sup>1</sup> · Gregory Lutz<sup>1</sup>

Received: 17 February 2016 / Accepted: 27 March 2016  
© SICOT aisbl 2016

## Abstract

**Purpose** The aim of this article is to provide an overview of clinical and translational research on intradiscal platelet-rich plasma (PRP) as a minimally invasive treatment for discogenic low back pain.

**Methods** A literature review of in vitro, in vivo, and clinical studies was performed.

**Results** There is strong in vitro evidence that supports the use of intradiscal PRP for discogenic low back pain. There are also promising findings in select preclinical animal studies. A clinical study of 29 participants who underwent intradiscal PRP injections for discogenic low back pain found statistically and clinically significant improvements in pain and function through two years of follow-up.

**Conclusions** Intradiscal PRP is a safe and a possibly effective treatment for discogenic low back pain. Future studies are warranted to determine the best candidates for this treatment, what the optimal injectate is and what relationships exist between patient-reported outcomes and radiological findings.

**Keywords** Biologic · Disc · Treatments

✉ Gregory Lutz  
lutzg@hss.edu

Michael Monfett  
MonfettM@hss.edu

Julian Harrison  
HarrisonJ@hss.edu; Jrh377@comell.edu

Kwadwo Boachie-Adjei  
Boachieadjeik@hss.edu

<sup>1</sup> Department of Physiatry, Hospital for Special Surgery, 429 E 75th Street, 3rd Floor, New York, NY 10021, USA

## Introduction

Throughout the world, low back pain (LBP) is a common and often complex problem for patients and physicians. As the most common cause of disability among Americans between 45 and 65 years of age [1], LBP affects approximately 80 % of adults, who will experience at least one episode of LBP during their lifetime [2]. Furthermore, LBP imposes a significant economic burden on the US healthcare system [3], amounting to the most costly musculoskeletal problem in the nation [4]. Most cases of LBP are self-limited; however, approximately 20 % recur within six months of the initial episode and a subset of patients experience chronic symptoms thereafter [4]. This subset of patients—which is often left with the difficult decision of either living with the pain or undergoing major spinal surgery—that may be candidates for intradiscal PRP therapy.

LBP can have many varied underlying aetiologies. Of all the causes, intervertebral disc (IVD) degeneration is one of the most prevalent, accounting for  $\geq 40$  % of chronic LBP [4]. The IVD plays an important role in maintaining mobility and stability of the adult spine [5]. Structurally, it comprises an inner nucleus pulposus (NP) and an outer fibrocartilaginous ring, named the annulus fibrosus (AF). The NP, composed of mainly water and proteoglycans, can bear heavy compressive loads due to its intrinsic hydrostatic pressure. The AF, composed of an extracellular matrix (ECM) mixed with both type I and II collagen, can resist heavy tensile stresses [5, 6]. The adult IVD is the largest avascular structure in the human body. Small branches of the metaphyseal arteries around the outer annulus comprise its limited vasculature, and therefore, the IVD must rely on passive diffusion from adjacent endplate vessels for nutrition [7]. Unlike bone, which has an adequate blood supply with great ability to repair and regenerate, the IVD has no intrinsic capacity for remodeling and repair. This limited vascular supply and largely indirect access to nutrition

results in poor inherent healing potential. IVD degeneration usually accompanies normal aging and is characterised by a loss of IVD homeostasis. This results in degradation and dehydration of the NP, followed by breakdown of the collagenous fibre bundles in the AF. Due to the homeostatic imbalance of the IVD, annular fissures develop, allowing for migration of NP contents into the outer AF. A variety of pro-inflammatory cytokines have been implicated in this process, including interleukin-1 beta (IL-1 $\beta$ ) and tumor necrosis factor alpha (TNF- $\alpha$ ). Upregulation of these cytokines can lead to chemical sensitisation of the rich network of nerve fibres that reside in the outer AF [8–10]. The combination of these events, with the inability of the IVD to heal after injury because of its limited vascular supply, lead to chronic pain characterised by the condition referred to as degenerative disc disease (DDD) [4].

Currently, the most common treatments available for DDD range from conservative strategies (physical therapy and anti-inflammatory medications) to minimally invasive interventional techniques (epidural injections and ablation techniques) to surgical options [11, 12]. Each of these strategies aims to provide symptomatic relief from clinical symptoms associated with DDD, but none actually target the specific underlying pathophysiology itself or reverse the degenerative process. Historically, the two most commonly employed techniques considered to be minimally invasive options were intradiscal electrothermal therapy (IDET) and nucleoplasty. Evidence for IDET reports short-term improvements in pain relief at six months of 40–75 % and long-term relief between 16 and 75 % [13–17]. The evidence for intradiscal electrothermal therapy (IDET) is considered strong for short-term and moderate for long-term relief in managing chronic discogenic LBP [18]. With regards to nucleoplasty, the evidence largely consists of prospective evaluations yielding limited evidence for nucleoplasty as a treatment option for lumbar discogenic pain. Open discectomy and microdiscectomy were recently evaluated by Cook et al., who found that less than half of 1,108 patients achieved at least 50 % improvement with regards to pain and disability outcomes following the procedure. Radicular pain greater than LBP was observed to be a strong prognostic indicator for discectomy [19]. Accordingly, in the absence of conspicuous morphologic deformity, indications for surgical intervention appear less substantiated. Reoperation after lumbar disc surgery was recently discussed by Cheng et al., who found that there was also still a notable population requiring reoperation and/or revision following primary operations targeting lumbar disc herniation [20]. With such variable results in treatments for IVD degeneration, studies involving other viable options focused on preventing, treating and possibly reversing the degenerative disc process, are ongoing. The ideal treatment option would not be harmful or destructive to tissue but would repair and/or regenerate the injured tissue. It would be cost

efficient, minimally invasive, sustainable, safe and readily available, and is supported by well-designed clinical studies.

There is mounting evidence suggesting that intradiscal injections of platelet-rich plasma (PRP) may help injured or degenerative discs. PRP is an autologous injectate derived from patients' own whole blood which is centrifuged to yield injectates concentrated with platelets and several biologically active soluble mediators of IVD homeostasis. The theory supporting the use of PRP in treating various musculoskeletal conditions is based on the concept of reparative healing. In this context, growth factors are considered essential in the healing process and tissue formation [21]. It is believed that in the earlier stages of DDD, the remaining functional cells within the IVD, when exposed to varied growth factors, respond with proliferation and extracellular matrix (ECM) accumulation, which helps to restore and preserve the structure and function of the degenerated IVDs [22]. PRP is considered extremely rich in these growth factors, which are contained within the platelet alpha granules. Of particular interest in the context of pain-generating IVDs are the high concentrations of fibrin, transforming growth factor beta (TGF- $\beta$ ), insulin-like growth factor-1 (IGF-1), basic fibroblast growth factor (bFGF), platelet-derived growth factor-BB (PDGF), and vascular endothelial growth factor (VEGF) [23–26]. Recently, there has been considerable interest in the utility of PRP in the treatment of degenerative IVD disease.

The objective of this article was to discuss and summarise the most recent literature, including *in vitro*, *in vivo* and clinical trials, focusing on the use PRP injectate in the setting of lumbar IVD-derived pain.

### **In vitro**

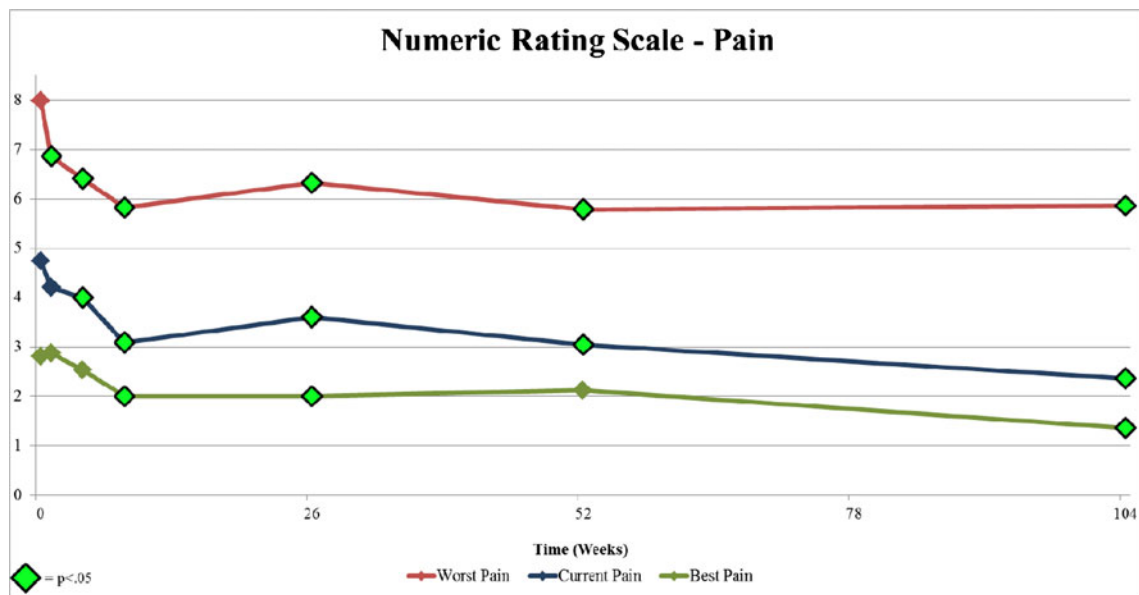
*In vitro* investigations on the regenerative potential of PRP on IVD cells report consistent results. Chen et al. [27] assessed PRP in a 2D culture of human NP cells to determine the proteoglycan accumulation and antiapoptotic effects demonstrated by NP cells. They reported that NP cell proliferation increased 7–11 times compared with controls, along with upregulated proteoglycan content. Around the same time, Akeda et al. [28] assessed the effects of PRP on porcine IVD ECM and found that IVD tissues cultured in PRP lead to upregulated synthesis of proteoglycans and collagen. Kim et al. [29] sought to understand what role PRP has in suppressing IL-1- and TNF- $\alpha$ -induced inflammation in human-derived NP cells and found that PRP leads to both a downregulation of proinflammatory cytokines and upregulated ECM synthesis. Similarly, Liu et al. [30] found that immortalised human NP cells previously exposed to lipopolysaccharides (LPS) underwent upregulation of chondrogenic markers and downregulation of inflammatory mediators and matrix-degrading enzymes following culture with PRP. More recently, Pirvu et al. [31] investigated the regenerative potential of PRP and platelet lysate (PL) on

bovine AF cells and concluded that both induced proliferative effects on AF cells and upregulation of ECM synthesis.

**In vivo**

While results collected *in vitro* are relatively consistent, the *in vivo* evidence for the effect of PRPs on disc degeneration appears more variable. Nagae et al. initially reported in 2007 [32] that autologous PRP embedded in gelatin microspheres found via immunohistochemical staining that IVD proteoglycan content was enhanced in a suction-induced DDD rabbit model at eight weeks following intradiscal administration of PRP. Two years later, the same group found that discs injected with PRP had significantly higher water content determined by magnetic resonance imaging (MRI), which corresponded with increased intradiscal proteoglycan content, upregulated messenger RNA (mRNA) precursors for type II collagen and

significantly reduced apoptotic NP cells [33]. Using a percutaneous annulus puncture-induced DDD rat model, Gullung et al. [34] found that discs treated with PRP had higher preservation of normal morphology, fewer inflammatory cells and higher fluid content, as evidenced by T2 MRI compared with sham at four weeks post-injection. Hou et al. [35] found that bone morphogenic protein-2 (BMP-2) transduced bone marrow mesenchymal stem cells when combined with a PRP gel scaffold could survive 12 weeks *in vivo* when injected into the injured discs of rabbits. They also demonstrated ECM restoration and preservation of NP histologic structures. Obata et al. [36] found that at eight weeks post-injection, rabbit discs injected with PL activated with calcium chloride had significantly higher disc height and number of NP cells than those injected with phosphate-buffered saline. While the PRP lysate group exhibited normalised T2 relaxation times that were consistently higher compared with saline controls at 8 weeks, this



		Baseline	1 Week	4 Weeks	8 Weeks	6 Months	1 Year	2 Years
Worst Pain	N:	29	29	28	29	28	24	22
	Follow-Up Rate:	-	100%	100%	97%	97%	92%	85%
	Mean:	7.98	6.86	6.41	5.82	6.32	5.79	5.86
	Standard Deviation:	1.56	1.94	1.85	2.33	2.12	2.17	2.80
	Change from Baseline:	-	-1.12	-1.57	-2.16	-1.66	-2.19	-2.12
	p-value:	-	0.001	0.000	0.000	0.000	0.000	0.003
	%MCID:	-	34%	38%	50%	46%	58%	45%
Current Pain	N:	29	29	29	29	28	24	22
	Follow-Up Rate:	-	100%	100%	97%	97%	92%	85%
	Mean:	4.74	4.21	4.00	3.09	3.60	3.04	2.36
	Standard Deviation:	2.21	1.99	2.21	2.59	2.49	2.71	2.72
	Change from Baseline:	-	-0.53	-0.74	-1.65	-1.14	-1.70	-2.38
	p-value:	-	0.057	0.015	0.000	0.004	0.001	0.000
	%MCID:	-	24%	28%	39%	43%	55%	55%
Best Pain	N:	29	29	29	28	28	24	22
	Follow-Up Rate:	-	100%	100%	97%	97%	92%	85%
	Mean:	2.81	2.88	2.53	2.00	2.00	2.13	1.36
	Standard Deviation:	1.78	1.83	1.83	2.06	2.33	2.33	1.73
	Change from Baseline:	-	0.07	-0.28	-0.74	-0.79	-0.69	-1.45
	p-value:	-	0.795	0.310	0.013	0.027	0.055	0.001
	%MCID:	-	17%	21%	21%	32%	36%	36%

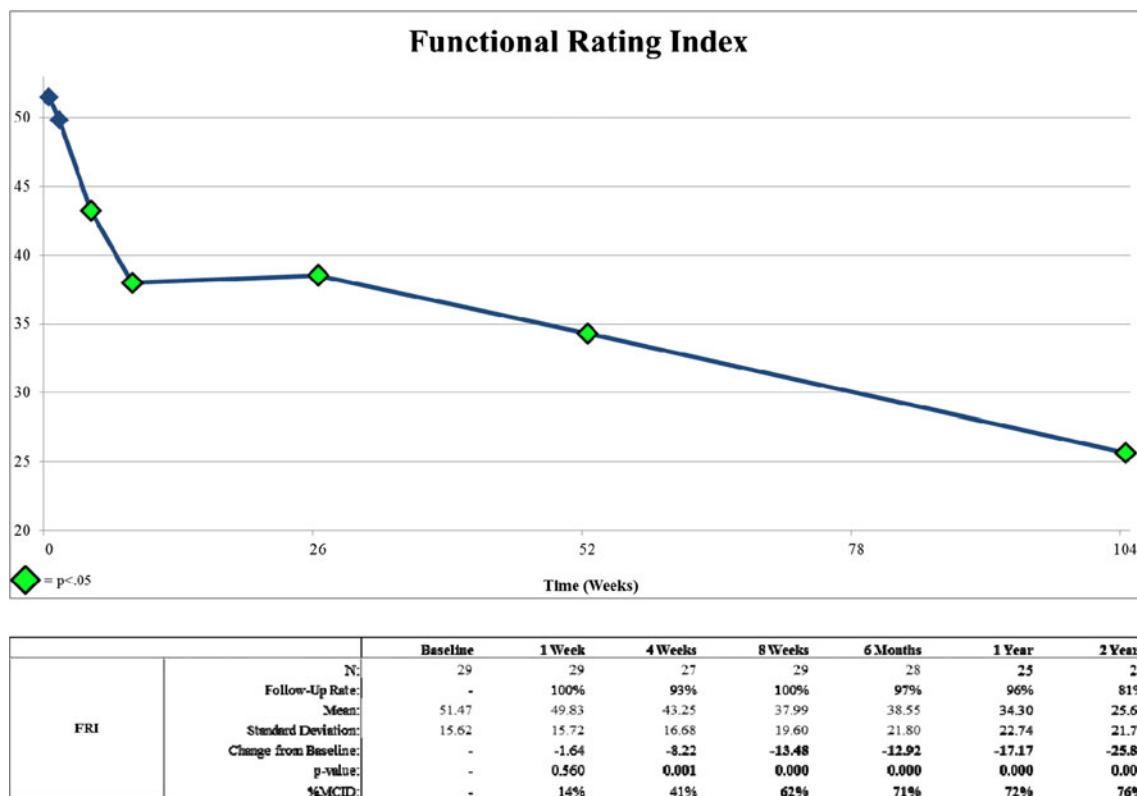
Fig. 1 Two-year longitudinal Numeric Rating Scale: pain results for participants who received intradiscal platelet-rich plasma (PRP)

difference lacked statistical significance. The results of the study conflict with those reported by Chen and colleagues [37], but as Obata et al. explain, this can likely be attributed to the use of a chymopapain-induced DDD model and PL prepared using thrombin, which has been shown to degrade cartilage tissues [38]. A more recent in vivo investigation using a rabbit AF puncture model found that intradiscal injection of PRP significantly hindered the progression of DDD as determined using modified Pfirrmann criteria [39]. However, as the MRI evaluators in that study were unblinded, the objectivity of these findings is unclear. Overall, variable methodologies in preclinical animal studies demonstrate a range of histologic and radiological changes that warrant further investigation both in translational and clinical settings.

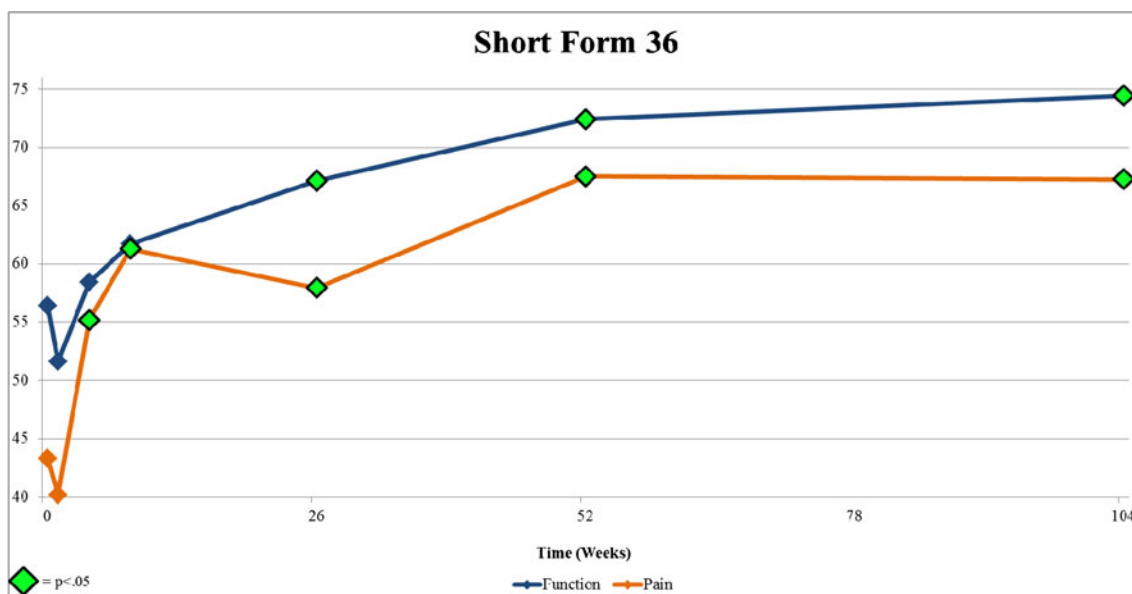
### Clinical trials

The utility of intradiscal PRP as a treatment for DDD was demonstrated recently in the clinical setting by Tuakli-Wosomu et al. [26]. They performed a DBRCT comprising 47 participants with DDD whose treatment group received single injections of autologous PRP versus the control group, who received contrast agent alone into symptomatic degenerative IVDs. The participants were analysed in terms of both pain and function using the Functional Rating Index (FRI), Numeric Rating Scale (NRS) for pain, the pain and physical function domains of the 36-item Short Form Health survey

(SF-36) and the modified North American Spine Society (NASS) Outcome Questionnaire. Participants were randomised into PRP versus control groups after provocative discography, and data was collected at baseline, one week, four weeks, eight weeks, six months and one year. Of note, participants who did not improve at eight weeks were offered the option to cross over to receive PRP treatment and were subsequently followed. At eight weeks, the authors found there were statistically significant improvements in those who received the intradiscal PRP compared with the control groups with regards to pain (NRS best pain), function (FRI) and patient satisfaction (NASS Outcome Questionnaire.) At the eight week time point, 68.2 % of control patients requested to be unblinded from the control arm of the study and received the PRP treatment. These participants were longitudinally followed as a separate arm after eight weeks. PRP and control group outcomes were not compared beyond the eight week time point. Longitudinal analysis was conducted on participants of the original PRP group at six months and one and two years. The authors found that there was improvement at each time point with regards to NRS best pain, FRI function, and SF-36 (both pain and function) in the PRP arm. Most impressively, there was clinically significant improvement sustained at two years post-injection for NRS worst pain  $-2.12$  points ( $p < .01$ ), FRI function  $-25.81$  points ( $p < .01$ ) and SF-36 pain  $+23.99$  ( $p < .01$ ) and SF36 function  $18.04$  ( $p < .01$ ) (Figs. 1, 2, and 3). Throughout the course of the trial, there were no adverse events of disc-space infection, neurologic



**Fig. 2** Two-year longitudinal Functional Rating Index results for participants who received intradiscal platelet-rich plasma (PRP)



		Baseline	1 Week	4 Weeks	8 Weeks	6 Months	1 Year	2 Years
Function	N:	29	29	28	29	28	24	21
	Follow-Up Rate:	-	100%	97%	100%	97%	92%	81%
	Mean:	56.40	51.63	58.43	61.70	67.14	72.41	74.44
	Standard Deviation:	18.52	20.46	21.17	22.89	24.18	23.84	24.98
	Change from Baseline:	-	-4.77	2.03	5.30	10.74	16.01	18.04
	p-value:	-	0.122	0.297	0.206	0.014	0.000	0.002
	%MCID:	-	38%	46%	55%	68%	79%	71%
Pain	N:	29	29	29	29	28	25	21
	Follow-Up Rate:	-	100%	100%	100%	97%	96%	81%
	Mean:	43.28	40.20	55.17	61.29	57.95	67.50	67.26
	Standard Deviation:	21.11	21.76	19.98	22.19	25.45	25.52	25.76
	Change from Baseline:	-	-3.08	11.89	18.01	14.67	24.22	23.98
	p-value:	-	0.561	0.004	0.001	0.001	0.000	0.004
	%MCID:	-	34%	55%	59%	54%	80%	67%

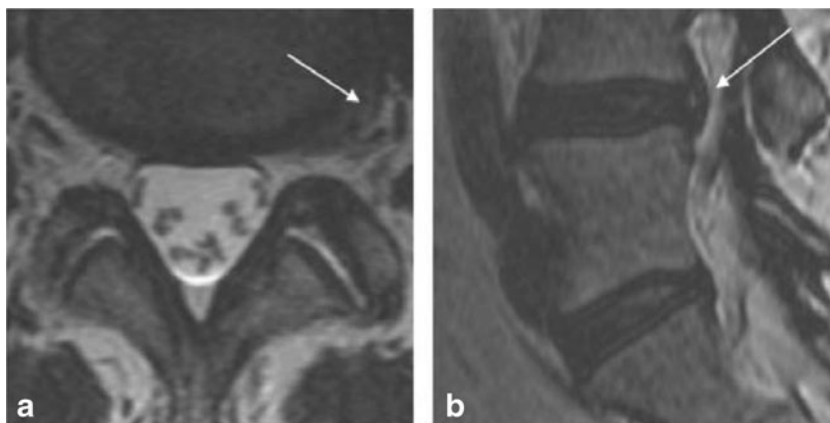
Fig. 3 Two-year longitudinal Short Form 36 pain and function results for participants who received intradiscal platelet-rich plasma (PRP)

injury or progressive herniation reported following the injection of PRP. With clinically significant and positive data through 104 weeks, the authors concluded that PRP is a safe and sustainable treatment option for discogenic pain. The authors encouraged further studies to look at ways to optimise the PRP injectate to potentially produce even better clinical results.

**Clinical case**

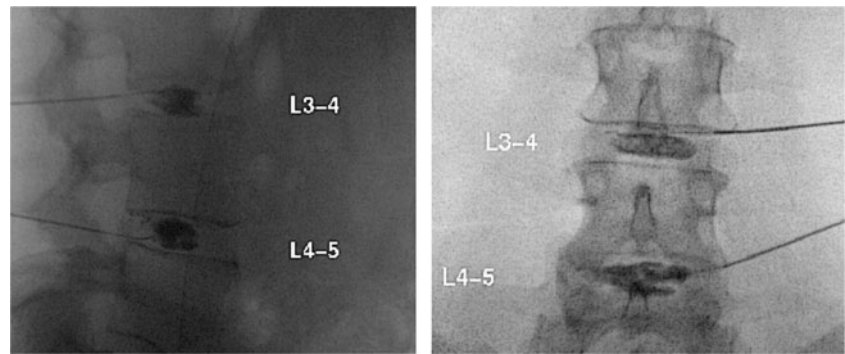
Dr. Gregory Lutz and his team at the Hospital for Special Surgery in New York have been using PRP for DDD for the past six years and provided us with a case example of the typical patient who responds to this type of therapy. The patient was a

Fig. 4 Axial and sagittal T2 magnetic resonance images (MRI) of the patient prior to intradiscal platelet-rich plasma (PRP) injection. Arrows highlight left L4-5 disc protrusion, with visible high-intensity zone





**Fig. 5** Sagittal and anteroposterior fluoroscopic images of the patient undergoing L3-4 and L4-5 provocative discography. An annular fissure is visible at L4-5 in the anteroposterior view



54-year-old woman with severe, chronic, LBP and left L4 radicular pain from a small left-sided foraminal disc protrusion (Fig. 4a, b). She reported trialing anti-inflammatory medications, physical therapies and even several interventional procedures at outside clinics. After two years of failed therapies and refractory pain, she underwent a two-level discogram, which was normal at L3-4 but at L4-5 provoked concordant pain (Fig. 5a, b), showing evidence of annular fissure. Postdiscography computed tomography (CT) scan images (Fig. 6a, b) revealed a grade IV annular tear. The patient had received 1.5 ml of autologous PRP at the time of discography and four weeks post-procedure, reporting near complete pain relief. At that time, the patient was re-enrolled in comprehensive physical therapy and followed in the clinic. At 18 months post-procedure, she continued to report sustained improvement in both pain and function (Fig. 7a, b).

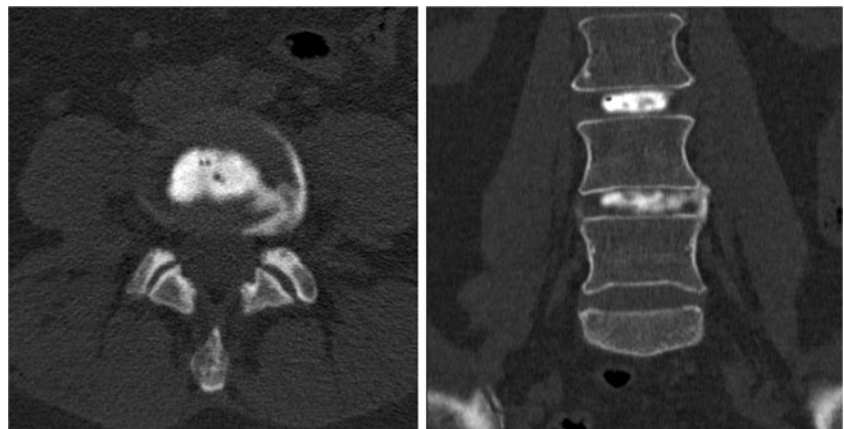
## Discussion

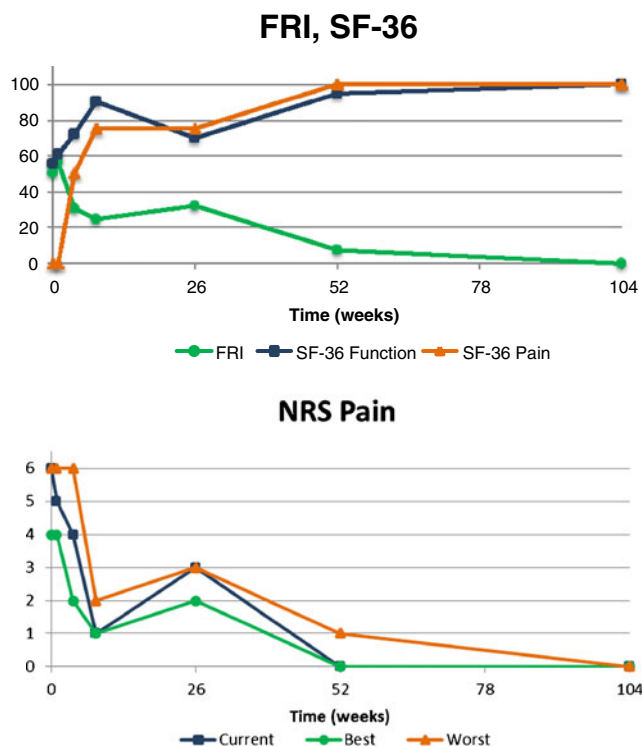
The pre-clinical and clinical studies summarised in this manuscript support intradiscal PRP as a safe and possibly therapeutic agent for this disabling condition, as well as being a sustainable cost-efficient treatment option. These procedures can be performed in the outpatient setting in about 30 minutes and are about one tenth the cost of a spinal fusion. However, further research is needed to elucidate the many unanswered

questions regarding its use. Just as Cooke et al. had described the presence of possible predictive factors for determining surgical outcome measures and optimal surgical candidates, further research is needed to discover characteristics that would suggest a nonsurgical intradiscal PRP interventional route may be a more favorable option in the setting of lumbar disc disease [19]. If an algorithm can be achieved to positively predict whether a surgical or nonsurgical route would best suite each patient, then not only would patient and physician satisfaction improve, but also a large economic burden may be lifted from the healthcare system in general. Illien-Junger et al. suggest that there may also be a role for injectable regenerative therapies used to augment surgical treatments at the time of intervention and serve as a protective tool against post-procedural degeneration for the IVD tissues [40]. The literature to date suggests that intradiscal PRP has the potential to not only fill this role but to prevent surgery in many patients. Future clinical trials should focus on determining optimal candidates to receive such treatments, optimal PRP concentration and composition, effects of receiving multiple injections, whether cellular physiology responsible for IVD regeneration can be targeted to optimise the therapeutic effect, whether any biomarkers or MRI variations exist that could serve as prognostic indicators and if there exists a role for augmenting surgical interventions with intra-operative PRP.

We believe we are at the onset of a paradigm shift in how patients with degenerative disc disease will be managed in the

**Fig. 6** Axial and anteroposterior computed tomography (CT) imaging of the study participant following provocative discography and injection of PRP at L4-5. A grade IV fissure with circumferential spread of contrast in the periphery of the annulus fibrosus is visible in the axial view





**Fig. 7** Two-year longitudinal Functional Rating Index (FRI), Short-Form 36 (SF-36) and Numerical Rating Scale (NRS): pain scores of the study participant following intradiscal platelet-rich plasma (PRP) injection at L4-5

future. Biologic therapies such as PRP not only offer hope for a cure to the most common, most costly and most disabling musculoskeletal condition faced by clinicians and patients, but may also offer national healthcare systems a cost-effective, sustainable solution to the management of LBP. The purpose of this manuscript was to introduce and summarise some of the most current work being done with PRP in the setting of DDD and to encourage, stimulate, and guide future research in regenerative spine medicine.

**Acknowledgments** The platelet-rich plasma preparation kits used in the clinical study included in this review were donated by Harvest Technologies.

#### Compliance with ethical standards

**Conflict of interest** Dr. Gregory Lutz is the Chief Medical Advisor for Biorestorative Therapies, LLC. The authors have no other financial interests to disclose.

## References

- Frank JW, Brooker AS, DeMaio SE et al (1996) Disability resulting from occupational low 353 back pain. part I: What do we know about primary prevention? A review of the scientific 354 evidence on prevention before disability begins. *Spine (Phila Pa 1976)* 21(24):2908–2917
- Andersson GB (1999) Epidemiological features of chronic low-back pain. *Lancet* 354(9178):581–585
- Frymoyer JW, Cats-Baril WL (1991) An overview of the incidences and costs of low back pain. *Orthop Clin North Am* 22(2):263–271
- Schwarzer AC, Aprill CN, Derby R, Fortin J, Kine G, Bogduk N (1995) The prevalence and clinical features of internal disc disruption in patients with chronic low back pain. *Spine* 20(17):1878–1883
- Roberts S (2006) Histology and pathology of the human intervertebral disc. *J Bone Joint Surg Am* 88(Suppl\_2):10
- Migacz K, Chłopek J, Morawska-Chochoł A, Ambroziak M (2014) Gradient composite materials for artificial intervertebral discs. *Acta Bioeng Biomech* 16(3):3–12
- Bogduk N (2005) Clinical anatomy of the lumbar spine and sacrum, 4th edn. Elsevier, USA, pp 147–148
- Weiler C, Nerlich AG, Bachmeier BE et al (2005) Expression and distribution of tumor necrosis factor alpha in human lumbar intervertebral discs: a study in surgical specimen and autopsy controls. *Spine* 30:44–53
- Le Maitre CL, Freemont AJ, Hoyland JA (2005) The role of interleukin-1 in the pathogenesis of human intervertebral disc degeneration. *Arthritis Res Ther* 7:R732–R745
- Hoyland JA, Le Maitre CL, Freemont AJ (2008) Investigation of the role of IL-1 and TNF in matrix degradation in the intervertebral disc. *Rheumatology* 47:809–814
- Di Martino A, Vaccaro AR, Yung Lee J, Denaro V, Lim MR (2005) Nucleus pulposus replacement: basic science and indications for clinical use. *Spine* 30(16 Suppl):S16–S22
- Di Martino A, Merlini L, Faldini C (2013) Autoimmunity in intervertebral disc herniation: from bench to bedside. *Expert Opin Ther Targets* 17(12):1461–1470
- Karasek M, Bogduk N (2000) Twelve-month follow-up of a controlled trial of intradiscal thermal annuloplasty for back pain due to internal disc disruption. *Spine* 25:2601–2607
- Bogduk N, Karasek M (2002) Two-year follow-up of a controlled trial of intradiscal electrothermal annuloplasty for chronic low back pain resulting from internal disc disruption. *Spine J* 2:343–350
- Gerszten PC, Welch WC, McGrath PM, Willis SL (2002) A prospective outcome study of patients undergoing intradiscal electrotherapy (IDET) for chronic low back pain. *Pain Physician* 5:360–364
- Lee MS, Cooper G, Lutz GE, Doty S (2003) Intradiscal electrothermal therapy (IDET) for treatment of chronic lumbar discogenic pain: a minimum 2-year clinical outcome study. *Pain Physician* 6:443–448
- Freedman BA, Cohen SP, Kuklo TR, Lehman RA, Larkin P, Giuliani JR (2003) Intradiscal electrothermal therapy (IDET) for chronic low back pain in active-duty soldiers: 2- year follow-up. *Spine J* 3:502–509
- Boswell MV, Trescot AM, Datta S, Schultz DM, Hansen HC, Abdi S, Sehgal N, Shah RV, Singh V, Benyamin RM, Patel VB, Buenaventura RM, Colson JD, Cordner HJ, Epter RS, Jasper JF, Dunbar EE, Atluri SL, Bowman RC, Deer TR, Swicegood JR, Staats PS, Smith HS, Burton AW, Klothe DS, Giordano J, Manchikanti L (2007) American Society of Interventional Pain Physicians. Interventional techniques: evidence-based practice guidelines in the management of chronic spinal pain. *Pain Physician* 10(1):7–111
- Cook CE, Arnold PM, Passias PG et al (2015) Predictors of pain and disability outcomes in one thousand, one hundred and eight patients who underwent lumbar discectomy surgery. *Int Orthop* 39(11):2143–2151
- Cheng J, Wang H, Zheng W et al (2013) Reoperation after lumbar disc surgery in two hundred and seven patients. *Int Orthop* 37(8):1511–1517
- Werner S, Grose R (2003) Regulation of wound healing by growth factors and cytokines. *Physiol Rev* 83:835–870

22. Wang SZ, Chang Q, Lu J, Wang C (2015) Growth factors and platelet-rich plasma: promising biological strategies for early intervertebral disc degeneration. *Int Orthop* 39(5):927–934. doi:10.1007/s00264-014-2664-8
23. Anitua E, Andia I, Arredondo B, Nurden P, Nurden AT (2004) Autologous platelets as a source for healing and tissue regeneration. *Thromb Haemost* 91:4–15
24. Bennett NT, Schultz GS (1993) Growth factors and wound healing: part II. Role in normal and chronic wound healing. *Am J Surg* 166(1):74–81
25. Kajikawa Y, Morihara T, Sakamoto H, Matsuda K, Oshima Y, Yoshida A et al (2008) Platelet-rich plasma enhances the initial mobilization of circulation-derived cells for tendon healing. *J Cell Physiol* 215(3):837–845
26. Tuakli-Wosornu YA, Terry A, Boachie-Adjei K, Harrison JR, Gribbin CK, LaSalle EE, Nguyen JT, Solomon JL, Lutz GE (2015) Lumbar intradiscal platelet rich plasma (PRP) injections: a prospective, double-blind, randomized controlled study. *PM R*. doi:10.1016/j.pmrj.2015.08.010
27. Chen WH, Lo WC, Lee JJ, Su CH, Lin CT, Liu HY, Lin TW, Lin WC, Huang TY, Deng WP (2006) Tissue-engineered intervertebral disc and chondrogenesis using human nucleus pulposus regulated through TGF-beta1 in platelet-rich plasma. *J Cell Physiol* 3:744–754
28. Akeda K, An HS, Pichika R, Attawia M, Thonar EJ, Lenz ME, Uchida A, Masuda K (2006) Platelet-rich plasma (PRP) stimulates the extracellular matrix metabolism of porcine nucleus pulposus and annulus fibrosus cells cultured in alginate beads. *Spine (Phila Pa 1976)* 31(9):959–966
29. Kim HJ, Yeom JS, Koh YG, Yeo JE, Kang KT, Kang YM, Chang BS, Lee CK (2014) Anti-inflammatory effect of platelet-rich plasma on nucleus pulposus cells with response of TNF- $\alpha$  and IL-1 $\beta$ . *Orthop Res* 32(4):551–556
30. Liu MC, Chen WH, Wu LC, Hsu WC, Lo WC, Yeh SD, Wang MF, Zeng R, Deng WP (2014) Establishment of a promising human nucleus pulposus cell line for intervertebral disc tissue engineering. *Tissue Eng Part C Methods* 20(1):1–10
31. Pirvu TN, Schroeder JE, Peroglio M, Verrier S, Kaplan L, Richards RG, Alini M, Grad S (2014) Platelet-rich plasma induces annulus fibrosus cell proliferation and matrix production. *Eur Spine J* 23(4):745–753
32. Nagae M, Ikeda T, Mikami Y et al (2007) Intervertebral disc regeneration using platelet-rich plasma and biodegradable gelatin hydrogel microspheres. *Tissue Eng* 13:147–158
33. Sawamura K, Ikeda T, Nagae M et al (2009) Characterization of in vivo effects of platelet-rich plasma and biodegradable gelatin hydrogel microspheres on degenerated intervertebral discs. *Tissue Eng Part A* 15:3719–3727
34. Gullung GB, Woodall JW, Tucci MA et al (2011) Platelet-rich plasma effects on degenerative disc disease: analysis of histology and imaging in an animal model. *Evid Based Spine Care J* 2:13–18
35. Hou Y, Shi G, Shi J, Xu G, Guo Y, Xu P (2015) Study design: in vitro and in vivo assessment of bone morphogenic protein 2 combined with platelet-rich plasma on treatment of disc degeneration. *Int Orthop*. 2015. PMID: 26169838
36. Obata S, Akeda K, Imanishi T, Masuda K, Bae W, Morimoto R, Asanuma Y, Kasai Y, Uchida A, Sudo A (2012) Effect of autologous platelet-rich plasma-releasate on intervertebral disc degeneration in the rabbit annular puncture model: a preclinical study. *Arthritis Res Ther* 14(6):R241
37. Chen WH, Liu HY, Lo WC, Wu SC, Chi CH, Chang HY, Hsiao SH, Wu CH, Chiu WT, Chen BJ, Deng WP (2009) Intervertebral disc regeneration in an ex vivo culture system using mesenchymal stem cells and platelet-rich plasma. *Biomaterials* 30:5523–5533
38. Furmaniak-Kazmierczak E, Cooke TD, Manuel R, Scudamore A, Hoogendorn H, Giles AR, Nesheim M (1994) Studies of thrombin-induced proteoglycan release in the degradation of human and bovine cartilage. *J Clin Invest* 94:472–480
39. Gui K, Ren W, Yu Y, Li X, Dong J, Yin W (2015) Inhibitory effects of platelet-rich plasma on intervertebral disc degeneration: a preclinical study in a rabbit model. *Med Sci Monit* 21:1368–1375
40. Illien-jünger S, Lu Y, Purmessur D et al (2014) Detrimental effects of discectomy on intervertebral disc biology can be decelerated by growth factor treatment during surgery: a large animal organ culture model. *Spine J* 14(11):2724–2732